





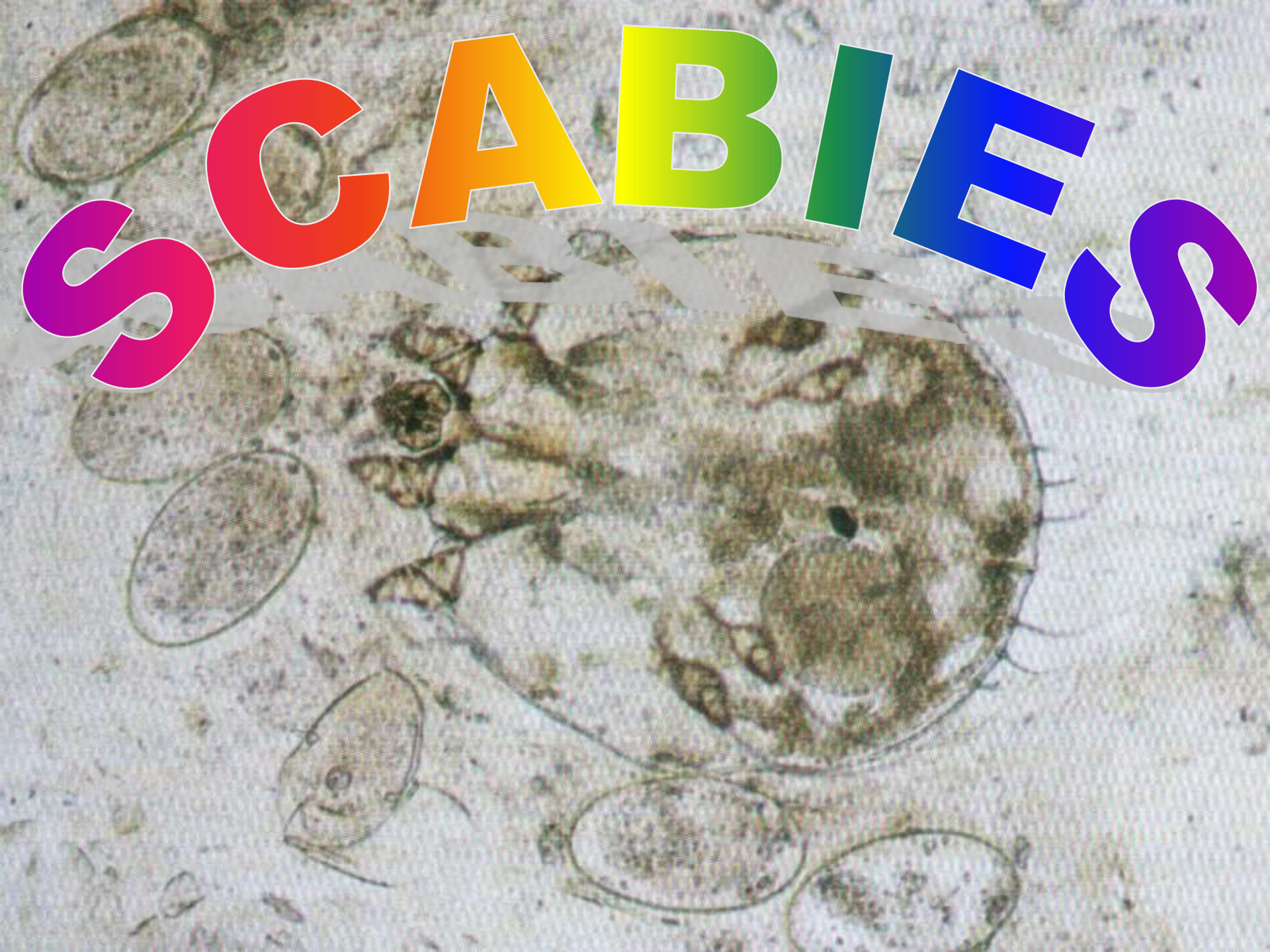
PARASITIC INFESTATIONS

Dr/ Ashraf Ahmed Abd El-Latif, MD.

Lecturer of Dermatology, Venereology and Andrology
Faculty of Medicine- Sohag University

2018

SCABIES



* **Diagnosis:**

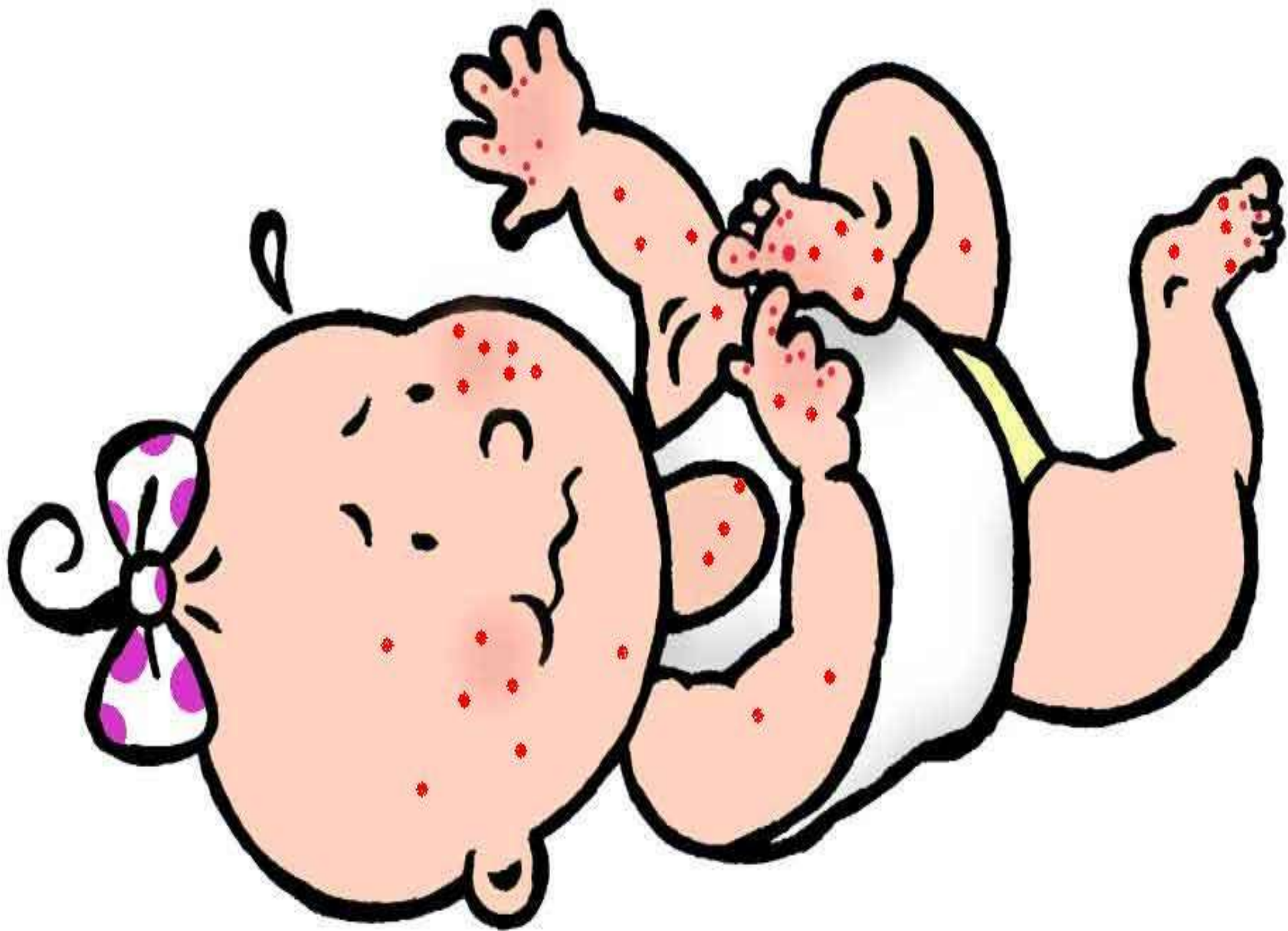
- Itching mainly at night (Unknown why ?? Host factors **x Not diurnal activity of the mite**)
- Presence of burrows
- Distribution of the lesions
- Contact cases within the family
- Demonstration of parasite under microscope

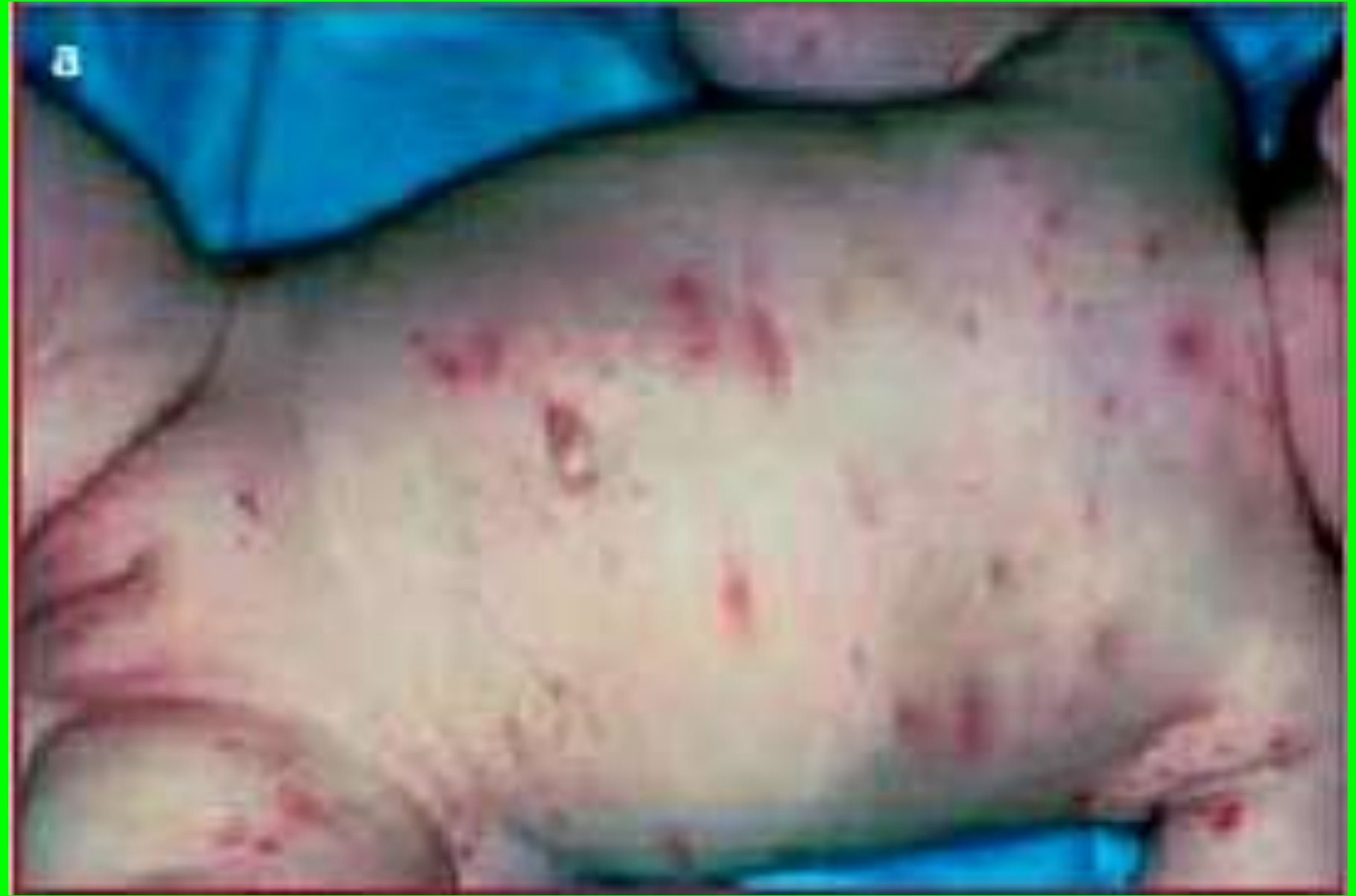*** Differential diagnosis:**

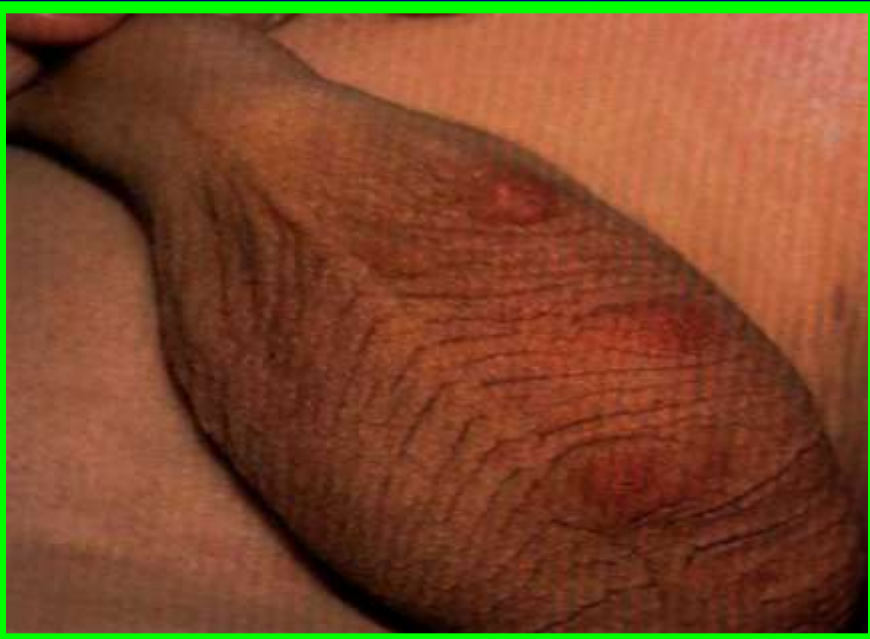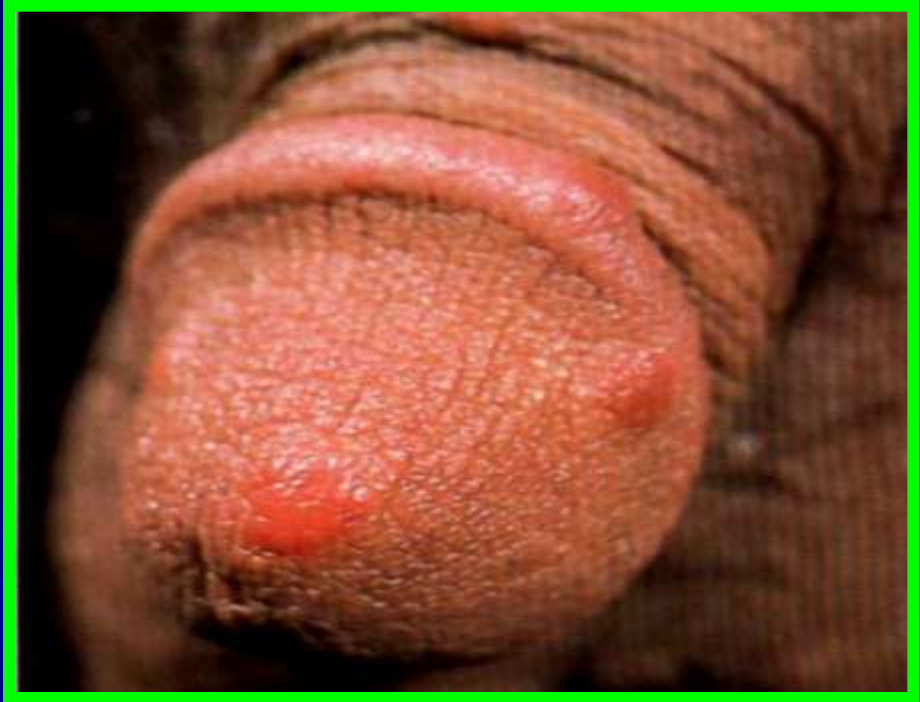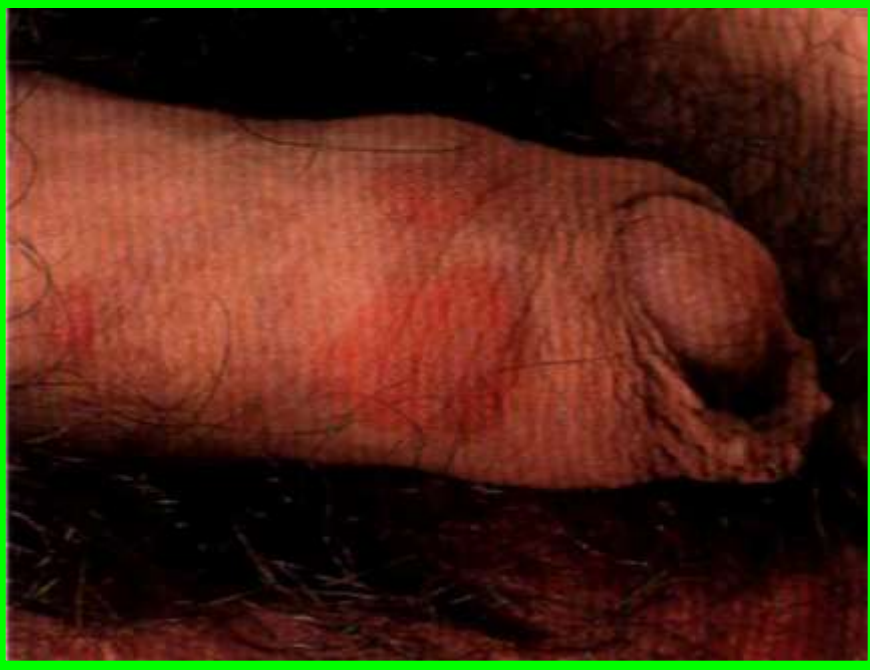1. Papular urticaria
2. Prurigo
3. Eczema
4. Pediculosis corporis

Clinical Varieties of Scabies

- Scabies in infants
- Scabies in the clean
- Scabies incognito
- Nodular scabies
- Animal scabies
- Norwegian scabies

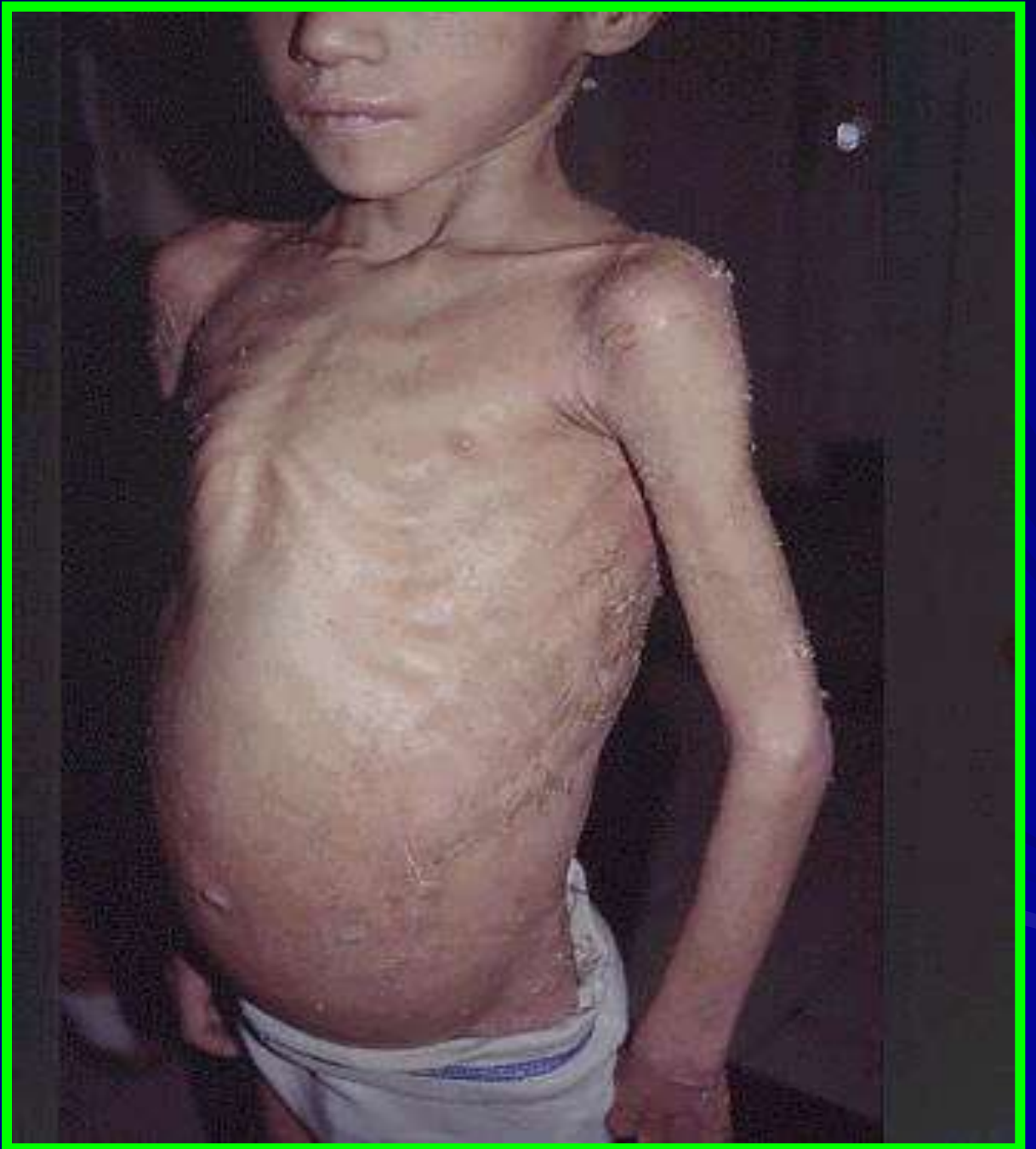


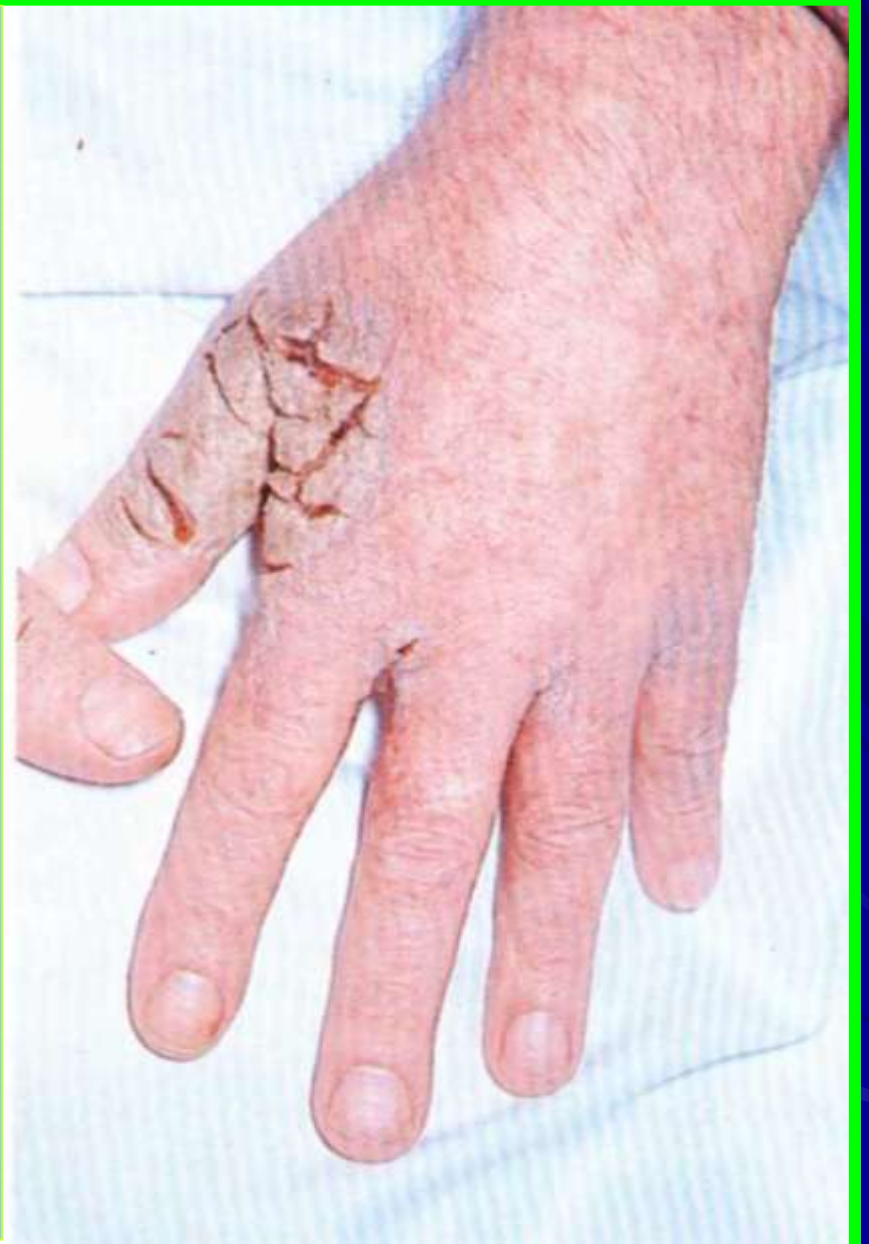
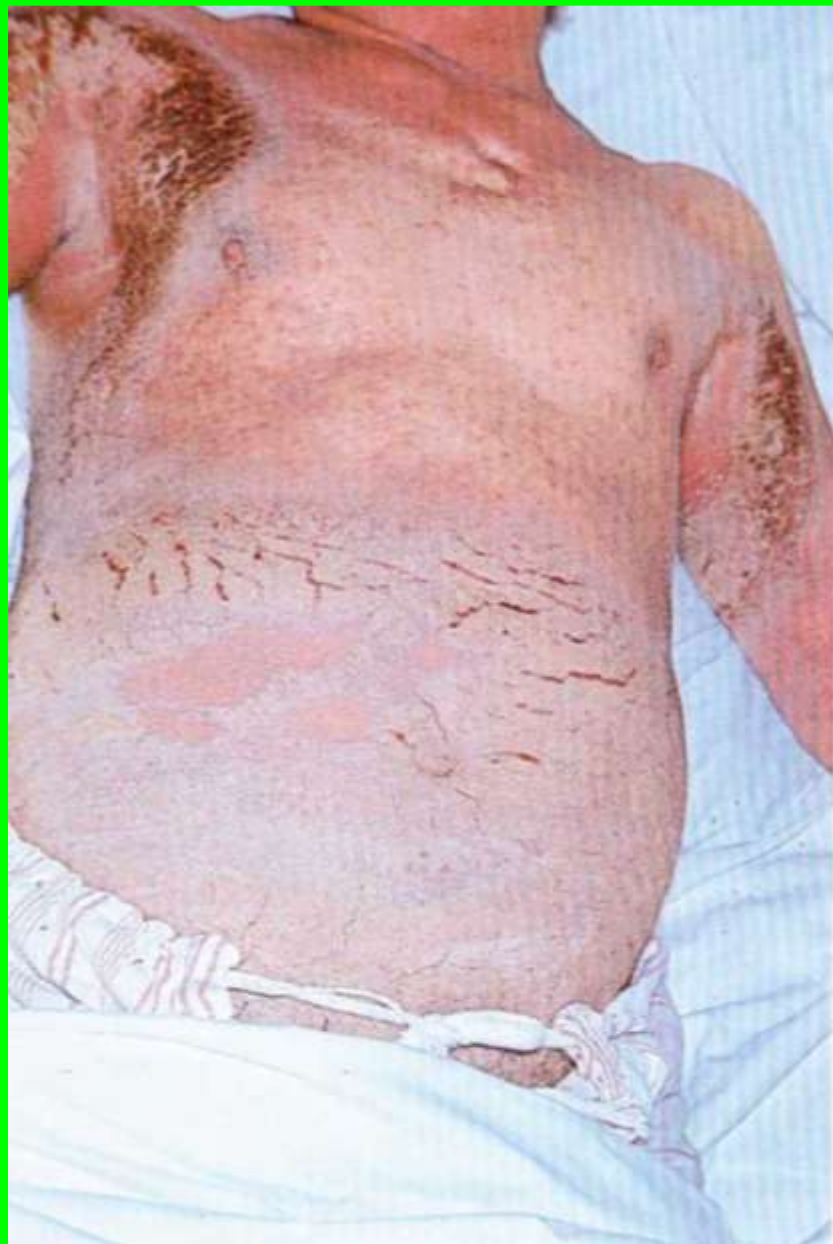

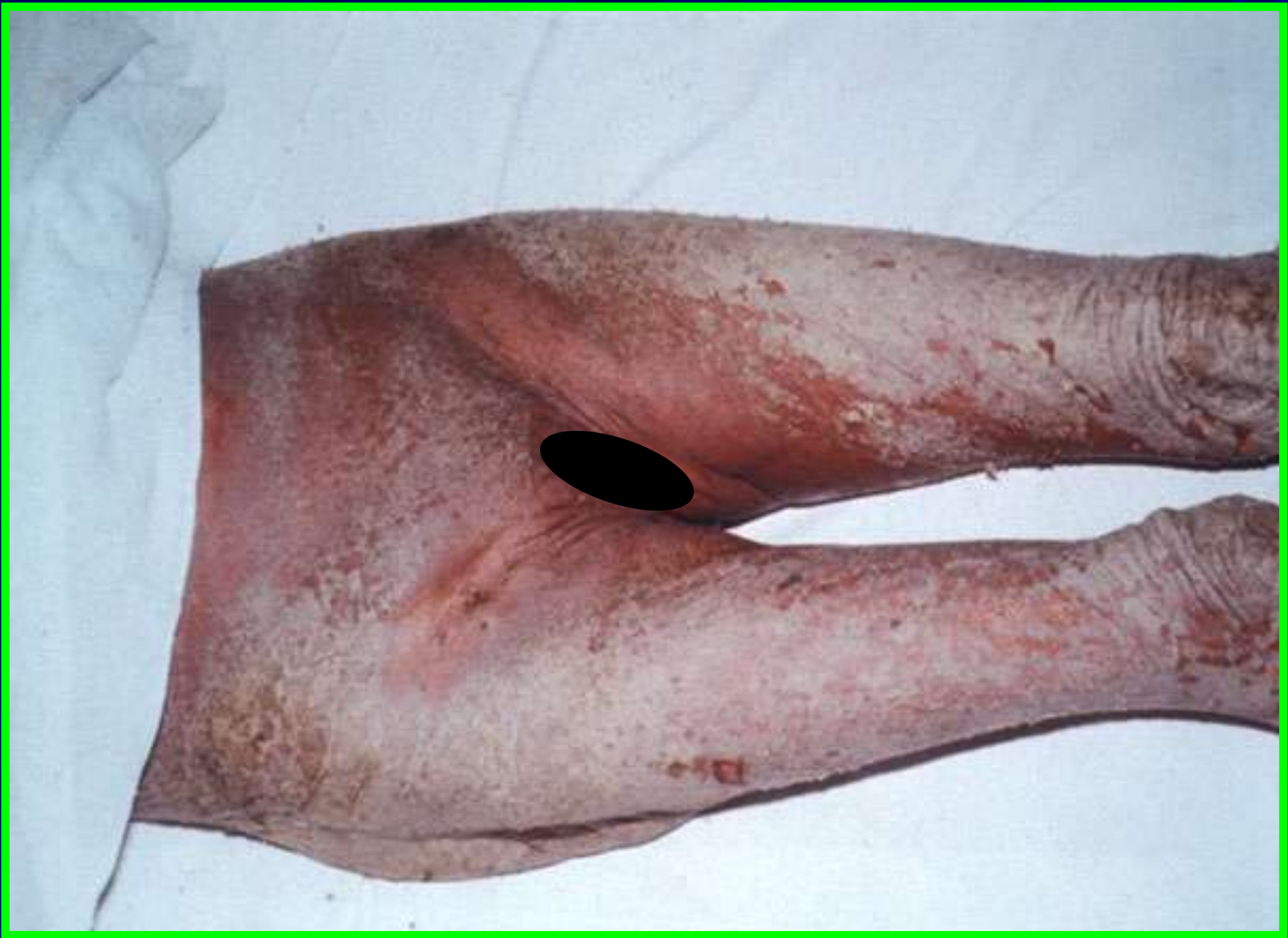Nodular scabies

Norwegian
scabies





Norwegian scabies



Animal scabies

- Animal variants of *sarcoptes scabiei* **CANNOT** infest humans (no copulation or burrow formation)
- They **CAN** live for a short period on human skin leading to pruritic papulo-vesicles, at the site of animal contact (hypersensitivity reaction).
- It is self-limited.

*** Complications of Scabies:**

- Secondary bacterial infection
- Eczematous changes
- Acarophobia

***causes of post-scabietic pruritis**

- 1) Irritation of skin by topical preparations
- 2) Post-scabietic nodules/pruritis
- 3) Acarophobia

* **Treatment:**

- **Prophylactic measures:** e.g early diagnosis, treatment, disinfection, treatment of other family members & treatment of infected animals
- Underwear, sleepwear, sheets, pillowcases and towels should be boiled at 50°C for 10min
- Outerwear and other furniture can be left unused for few weeks (mite dies away from host)

■ Topical treatment:

1. Permethrin 2.5 – 5%
2. Crotamiton 10%
3. Benzyl Benzoate 25%
4. Gamma benzene hexachloride 1%
5. Malathion 1 %
6. Ivermectin
7. Sulfur 3-10%

■ **What should be done BEFORE applying the antiscabitic?**

- Cut the fingernails & toenails short
- Remove rings and watchbands
- Take a warm shower, then dry with a clean towel

■ Systemic treatment:

- 1) Ivermectin (400 µg/kg)
- 2) Antihistamines for itching
- 3) Antibiotics for 2ry bacterial infection

■ Intralesional steroid injection for post-scabetic nodules